

Orofacial and systemic manifestations in 212 paediatric HIV patients from Chennai, South India

KANNAN RANGANATHAN¹, ELUMALAI GEETHALAKSHMI¹, UMADEVI KRISHNA MOHAN RAO¹, KAAZHIVUR MUDIMBAIMANNAR VIDYA¹, NAGALINGESWARAN KUMARASAMY² & SUNITI SOLOMON²

¹Department of Oral Pathology, Ragas Dental College and Hospital, Uthandi, Chennai, and ²YRG CARE for AIDS Research and Education, Chennai

International Journal of Paediatric Dentistry 2010; 20: 276–282

Background. Lesions in the mouth and in other tissues and organs (oral and systemic lesions) in paediatric HIV infection are diverse and show differences in clinical presentation and severity from that of adults. Very little data exist for oral lesions in paediatric population in India.

Aim. To document and study oral and more widespread lesions in paediatric HIV seropositive patients.

Design. A cross-sectional study.

Setting. Paediatric HIV seropositive patients at tertiary centers: Ragas Dental College and Hospital and YRG CARE, Chennai, India.

Patients and methods. Two hundred and twelve paediatric HIV patients aged 0–14 years seen over a period of 1 year were included in the study. Clinical history, oral and systemic examinations

were recorded by qualified dental surgeons and physicians.

Results. One hundred and thirty-two patients had oral lesions ranging in number from one to three. Oral lesions included oral candidiasis (OC) (56.1%), gingivitis (10.8%), oral pigmentation (6.1%), depapillation of the tongue (5.7%), ulcers (4.2%), and oral hairy leukoplakia (1.4%). The most common systemic lesion observed was nonspecific lymphadenopathy (74.1%) followed by pruritic eruptions (53.8%), measles (51.4%), and tuberculosis (TB) (49.1%). Thirty-three (26%) patients were not immunosuppressed, 74 (58%) were moderately immunosuppressed, and 20 (15%) were severely immunosuppressed. Oral lesions exhibited positive correlation with lesions in other parts of the body.

Conclusion. Oral lesions are a common feature in paediatric HIV infection. Their management is vital to improve the quality of life of the infected children.

Introduction

The global estimate of children living with HIV infection in 2007 was 2.7 million¹. In India, the National AIDS Control Organization estimates that the 2.31 million living with HIV/AIDS, children aged less than 14 years comprise 3.4%². The route of HIV transmission in children is predominantly vertical transmission and blood transfusion. Routes of vertical transmission include: (i) transplacentally, during pregnancy; (ii) as the infant passes through the birth canal during

delivery; or (iii) postnatally, during breast-feeding³. The chief mode of HIV transmission to children in India is through the vertical route^{4,5}. Almost half of the infected infants are clinically symptomatic in the first year of life. The immature immune system predisposes a vertically infected child to a rapid and fulminant disease process⁶. Oral lesions are features of HIV infection and are well described in the literature in adults and our earlier studies have concurred with the findings from developed countries that oral lesions are diagnostic of HIV infection and that they are useful in monitoring HIV disease progression^{7–9}. Oral lesions in paediatric HIV infection are characteristic of the disease process and though, similar to adults, certain lesions are typical in the paediatric population⁶. Oral lesions in the paediatric HIV population have been reported from Brazil,

Correspondence to:

Dr. K. Ranganathan, Department of Oral and Maxillofacial Pathology, Ragas Dental College and Hospital, 2/102, East Coast Road, Uthandi, Chennai-600119, India.

Tel: +91 44 24530002

Fax: 91 44 24530009

E-mail: ranjay22@gmail.com

Romania, USA, Thailand, and South Africa, but little is known about the nature of oral lesions in HIV seropositive children in India^{6,10–13}. The present study was performed to understand the scope of oral lesions with respect to manifestations elsewhere in the body, as all are necessary for the overall management of HIV infected children.

Materials and methods

Study design

Cross-sectional study of 212 consecutive HIV seropositive patients seen over a period of 1 year (December 2004–2005).

Study subjects

The study group consisted of 212 HIV seropositive children. All the children were between 6 months to 14 years of age and had a confirmatory diagnosis by ELISA and/or Western blot. None were on antiretroviral therapy. Informed consent as approved by the institutional review board was obtained from the child's guardian for clinical examination and photographic documentation. All the clinical details were noted in preformatted case sheet. The oral lesions were diagnosed based on the EC Clearing House diagnostic criteria for paediatric patients and our earlier report by qualified dental surgeons^{8,14}. General examination was carried out by qualified physicians and the findings recorded. Preliminary identification of *Candida albicans* in cases of clinical oral candidiasis was done by the germ tube technique following swab inoculation and culture on Sabouraud's dextrose agar¹⁵.

Statistical analysis

Data entry, database management and analysis were done using SPSS[®] version 11.0.5. Univariate Chi-square tests were performed to analyze the following variables: sex, age, route of transmission, pattern of feeding, past medication, CD4 count, lesions in other tissues/organs, oral lesions, and the type of clinical candidiasis. Pearson's correlation test

and odds ratio at 95% confidence interval were calculated to determine the association between oral lesions and those elsewhere in the body.

Results

Demographic data

Patient profile, mode of HIV transmission, and the feeding pattern are given in Table 1. The most common route of HIV infection was through the vertical route (89.2%). Ages ranged from 6 months to 14 years with a mean 6.4 (± 3.4) years. Past medical history revealed that 66.4% (95 of 212) patients had received antituberculosis treatment (ATT) and 7.7% (11 of 212) alternative medications (siddha and homeopathic treatments) for various opportunistic infections.

Immune status

CD4 counts were available for 127 children. All the CD4 counts were done within three of the oral examination. 26% (33 of 127) were not immunosuppressed, 58% (74 of 127) were moderately immunosuppressed, and 15% (20 of 127) were severely immune suppressed; this classification being based on the 1994 revised classification system for paediatric HIV disease; based on CD4 cell counts that change according to the age of the child. Children less than 12 months of age were

Table 1. Demographic characteristics of 212 HIV positive paediatrics patients.

Variables	Males N = 120 (56.6%) N (%)	Females N = 92 (43.4%) N (%)	Total N = 212 N (%)
Age group			
<12 months	1 (0.8)	2 (2.2)	3 (1.4)
1–5 years	53 (44.2)	39 (42.4)	93 (43.4)
6–14 years	66 (55)	51 (55.4)	117 (55.2)
Route of transmission			
Vertical	105 (87.5)	84 (91.3)	189 (89.2)
Blood transfusion	9 (7.5)	2 (2.2)	11 (5.2)
Unknown	6 (5)	6 (6.5)	12 (5.7)
Feeding			
Bottle	8 (6.7)	7 (7.6)	15 (7.1)
Breast	65 (54.2)	45 (48.9)	110 (51.9)
Combination	23 (19.2)	22 (23.9)	45 (21.2)

considered severely immunosuppressed, moderately immunosuppressed, and not immunosuppressed at all when their CD4 counts were <750, 750–1499, and >1500 cells/mm³ respectively. Children between 1 and 5 years were considered severely immunosuppressed, moderately immunosuppressed, and not immunosuppressed at all when their CD4 counts were <500, 500–999, and >1000 cells/mm³ respectively. Children between 6 and 14 years considered severely immunosuppressed, moderately immunosuppressed, and not immunosuppressed at all when their CD4 counts were <200, 200–499, and >500 cells/mm³ respectively¹⁶.

Oral lesions

Table 2 shows the number of oral lesions in the study population. A total of 43.4% had at least one oral lesion and 2.3% had more than three oral lesions at the time of examination. There was no statistically significant correla-

Table 2. Number of oral lesions in paediatric HIV patients.

No. of oral lesions in 212 patients	n (%)
0	80 (37.7)
1	92 (43.4)
2	34 (16)
≥3	6 (2.8)

tion between the number of oral lesions and the immune status.

Figure 1 depicts the oral lesions in the study cohort. Oral candidiasis (OC) was the most prevalent lesions 56.1% (119 of 212) of which pseudomembranous candidiasis (PC) was seen in 50% (106 of 212), angular cheilitis (AC) in 20.3% (43 of 212), erythematous candidiasis (EC) in 16.5% (31 of 212), and hyperplastic candidiasis (HC) in 1.4% (3 of 212). Oral pigmentation was present in 13 patients (6.1%). Pigmentation was on the dorsal surface of tongue, hard palate, and on the buccal mucosa.

Lesions detected elsewhere in the body are depicted in Fig. 2. Generalized lymphadenopathy was the most common lesion 74.1% (157 of 212) followed by pruritic eruptions in 53.8% (114 of 212).

Oral candidiasis and other lesions

The lesions detected elsewhere in the body in our cohort were pulmonary TB diagnosed by chest radiographs, measles, otitis media, mumps, and scabies affecting skin on the generalized body surface. TB was found to be significantly associated with OC (OR 3.4 : 95% CI 1.9–6.1: $P < 0.001$). Measles and otitis also showed significant association with the presence of OC [measles (OR: 2.3), (OR: 2.7)] (Table 3). There was also a statistically significant association between tuberculosis and oral pigmentation ($P \leq 0.01$).

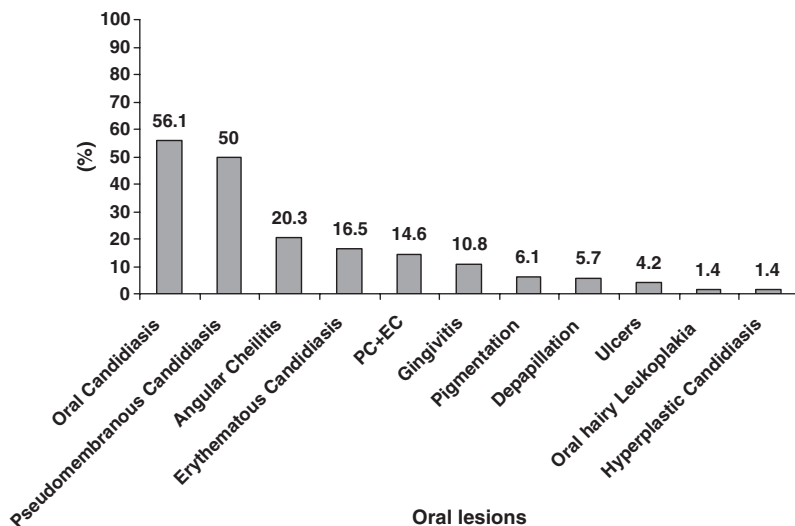


Fig. 1. Oral lesions in 212 paediatric HIV patients.

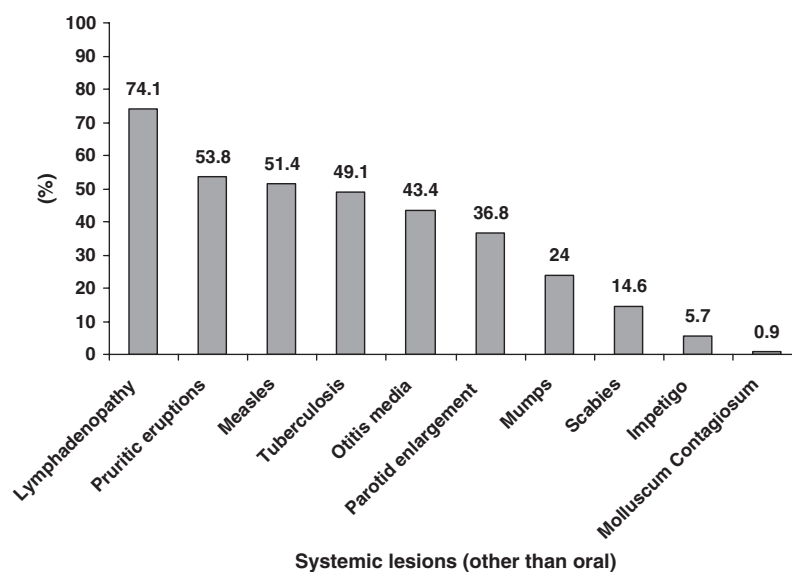


Fig. 2. Systemic lesions (other than oral) in the body in 212 paediatric HIV patients.

Table 3. Correlation between oral candidiasis and systemic lesions (other than oral) among HIV-infected paediatric patients.

Systemic OI	Odds ratio	95% CI	P value
Tuberculosis	3.453	1.951–6.114	0.00**
Otitis media	2.701	1.526–4.782	0.001**
Measles	2.319	1.332–4.037	0.003**

CI, confidence interval.

**Correlation significant at 0.01.

Discussion

Globally, 94% of paediatric HIV infections are said to be acquired vertically, with the vast majority being acquired during delivery^{16,17}. In developing countries, the route of HIV transmission to children is predominantly by the vertical route: 20% of the children before childbirth, 40% during childbirth, and 40% during breastfeeding³. In our study, the predominant mode of acquiring HIV infection was by vertical transmission (89.2%) similar to the 87% and 83% reported in earlier Indian studies^{4,5}.

Paediatric HIV infection is associated with a wide spectrum of oral lesions^{6,12,13}. Though the clinical features of HIV infection are similar in adults and children, they may vary in severity¹⁶. Oral mucosal lesions are one of the earliest clinical indicators of HIV infection and progression in children and are strongly associated with immune suppression¹⁷.

Though oral lesions are described as being more severe with increasing immunosuppression⁶ this was not the case in our study; this might be explained by the fact that CD4 counts were available for only 127 of our patients.

In this study the most common oral lesion was OC, seen in 56.1% of the patients which was similar to the frequencies of 63% and 67% reported from South Africa and USA, respectively^{6,12}. Clinically, candidiasis in an HIV infected child may present as creamy white pseudomembranous plaques, erythematous patches, angular cheilitis, nonscrapable hyperplastic plaques or as combination of these¹⁸. PC was the most common form of OC (50%) followed by angular cheilitis (20.3%) and EC (16.5%), similar to reports in paediatric cohorts from South Africa, Brazil, and Thailand^{6,13,19}. Hyperplastic candidiasis, though rarely reported in children²⁰, was present in three children (1.4%), aged 8, 9, and 10 years and of the three, two were females and one was a male child. Our earlier study reported HC prevalence of 1% in adults⁹. Combined lesions of PC and EC was seen in 14.6% and 5.7% of patients had depapillation of the dorsum of tongue, cultures from which were positive for *C. albicans*. Similar lesions have been reported from USA in 5% of 37 HIV infected paediatric patients²¹.

Conventional gingivitis was present in 10.8%; however, there were no cases of

linear gingival erythema. Gingivitis has also been reported from Brazil, UK and USA, even though these studies have suggested an association between conventional gingivitis and immunosuppression, we ourselves did not find a statistically significant association. This could be because of the limited CD4 data available to us^{10,22,23}.

Oral hairy leukoplakia (OHL) was present in 1.4% of patients similar to frequencies reported from Romania, South Africa, and the USA (2%, 1% and 2%) respectively^{6,11,24}. The high prevalence of OHL (22.5%) reported in Thai children reflects the high prevalence reported in Thai adults¹³. This has been attributed to the nonavailability of antiretroviral drugs and it may be similar to the endemicity of Epstein–Barr virus in adult HIV seropositive population seen in Thailand¹³.

The anaemia and associated nutritional deficiency causes epithelial atrophy and predisposes to mucositis both of which lead to abnormal oral melanin pigmentation²⁵. Our earlier studies have documented increased prevalence of oral pigmentation in HIV seropositive adults²⁶. In addition to anaemia, other causes of pigmentation are the release of α melanocyte-stimulating hormone caused by dysregulation of cytokines in HIV disease, Addison's disease, and drug induced (antiretroviral therapy)^{9,26}. Aphthous ulcers were present in nine patients (4.2%) with buccal mucosa, being the most common site. This finding was similar to the frequencies of 5% reported from Brazil and USA^{19,27}.

In our study the most common lesions detected in other parts of the body was persistent generalized lymphadenopathy (74.1%). This was similar to reports from Italy and Africa^{6,28}. HIV virus primarily infects the lymphocytes, and lymph node involvement is a persistent finding during all stages and is also a consistently seen sign throughout the clinical course of HIV infection²⁹.

Measles was seen in 51.4% of the children which is the highest reported in HIV infected paediatric patients, higher than 19% reported from Abidjan, Africa³⁰. This higher prevalence was due to the fact that even with mandatory imposition of the vaccination protocol advised in India, the awareness of the protocol and

adherence to the vaccination schedule was poor in our cohort. Poor adherence to the vaccination protocol may reflect the fact that the patients were from a lower socioeconomic status with constraints in health care accessibility. Many of our patients were not able to give a history of vaccination as either the parent/guardian were illiterate or some of the children were orphans.

Pulmonary tuberculosis is one of the most common systemic opportunistic infections in HIV infected individuals, particularly in India with a prevalence of 2.8–9.4%³¹. In this study, 49.1% had tuberculosis. Reports of TB range from 11.2% to 55% from Ethiopia and New York respectively^{32,33}. Consequently, HIV can predispose to TB and TB can worsen immunosuppression in the HIV infected.

Other opportunistic infections seen in this study were otitis media (43.4%), parotid enlargement (36.8%), and mumps (24.1%). Otitis media is often frequently caused by *Streptococcus pneumoniae* in immunosuppressed children³⁴. Microbiological tests for identification of *S. pneumoniae* was not done in this study and all patients were treated with wide spectrum antibiotics. Noninfective parotid gland enlargement in HIV infection is caused by infiltration of CD8+ cells that are cytotoxic to virally infected cells and have the ability to destroy the virus¹⁶. It has been suggested that in children with diffuse infiltrative lymphocytosis syndrome, HIV disease progresses slowly and patients survive longer. Further studies are required to confirm this hypothesis¹⁶.

Skin lesions affect more than 90% of HIV seropositive patients; lesions include papillary pruritic eruptions, herpes simplex and zoster, cutaneous tuberculosis, drug reactions and neoplasms³⁵. In our cohort, the cutaneous lesions seen included scabies (14.6%), impetigo (5.7%), and pruritic eruption without eczema (53.8%) which is less than that reported from Mumbai wherein pruritic eruption and eczema were seen in (83.3%) of patients of similar age and socioeconomic status³⁶. Scabies is a skin infestation caused by the mite *Sarcoptes scabiei*. Nodules and papules are seen in and around the axillae, digital webs, thighs, and wrists. It is extremely

pruritic. In advanced HIV disease ($CD4 < 150/mm^3$), the nodules take on a crusted appearance harbouring millions of mites instead of the 6–7 seen in immunocompetent subject³⁷. Two (0.9%) cases of molluscum contagiosum (MC) were seen in this study. One study from India reports three cases of MC out of 285 patients and another from Romania reports a frequency of 3%^{4,11}.

Oral candidiasis had a significant association with measles, tuberculosis, and otitis media ($P < 0.05$). Oral pigmentation had a significant association with tuberculosis ($P < 0.05$). Patients who presented with oral candidiasis had a higher risk of having tuberculosis (OR: 3.4), measles (OR: 2.3), otitis media (OR: 2.7), mumps (OR: 1.78), and scabies (OR: 0.59). This association of oral candidiasis and tuberculosis has been reported earlier^{9,38}. Increased systemic opportunistic infection in patients with oral candidiasis suggests that oral candidiasis has the potential to be used as a surrogate indicator for systemic opportunistic infections in the paediatric HIV patients and it reflects the degree of immunosuppression. Early detection of these lesions by dental practitioners will help in initiating prophylactic treatment against systemic opportunistic infections and significantly reducing associated morbidity, particularly in children where they tend to take a fulminant course.

Conclusions

- Systemic and oral mucosal lesions were a significant feature of HIV infection in the paediatric population. Oral candidiasis was significantly associated with the degree of immunosuppression and has the potential to be used as surrogate marker for systemic lesions.
- The dentist has a major role in early detection of the opportunistic infections and diagnosis of HIV infection in resource constrained countries. Furthermore, additional studies investigating the association between oral lesion and CD4 counts in a large sample size would be beneficial for developing markers for prognosis and treatment protocol for HIV infected chil-

dren in developing countries like India. More importantly, baseline data of antiretroviral (ART) naïve HIV infected are needed to understand the changes during ART therapy, which is becoming more easily available in India.

What this paper adds

- To our knowledge this is the first study in a large paediatric HIV cohort from India.
- We for the first time report hyperplastic candidiasis and oral pigmentation in paediatric HIV patients.
- Oral candidiasis correlated with some of the systemic lesions like tuberculosis and otitis media.

Why this paper is important to paediatric dentists

- This is the largest cohort of oral lesions in paediatric patients reported from south India. This information would not only fill the lacunae with respect to oral lesion in paediatric HIV infection but also provide valuable baseline data of HAART naïve patients.
- This data would be valuable in the future longitudinal studies to address:
 - (a) Pattern of oral lesions in evolving HIV infection
 - (b) Alterations of oral lesions, if any, post-HAART therapy
 - (c) Identification of potential surrogate marker (oral lesion) of immunosuppression

References

- 1 AIDS epidemic update 2008 UNAIDS/WHO (2007) working group on global HIV/AIDS surveillance. March: <http://www.unaids.org>.
- 2 National Aids Control Organisation. Monthly update (March 2009) Surveillance of HIV infection /AIDS cases India. <http://www.nic.in/naco/update.html>.
- 3 Centers for Disease Control. 1994 Revised classification system for human immunodeficiency virus infection in children less than 13 years of age. *MMWR Morb Mortal Wkly Rep* 1994; **43**: 1–10.
- 4 Merchant RH, Oswal JS, Bhagwat RV *et al*. Clinical profile of HIV infection. *Indian Paediatrics* 2001; **38**: 239–246.
- 5 Shah I. Age related clinical manifestations of HIV infection in Indian children. *J Trop Pediatr* 2005; **51**: 300–303.
- 6 Naidoo S, Chikte U. Oro-facial manifestations in paediatric HIV: a comparative study of institutionalized and hospital out patients. *Oral Dis* 2004; **10**: 13–18.
- 7 Greenspan JS. Sentinels and signposts: the epidemiology, significance of the oral manifestations of HIV disease. *Oral Dis* 1997; **3**: S13–S17.
- 8 Ranganathan K, Reddy BVR, Kumaraswamy N *et al*. Oral lesions and conditions associated with Human

- Immunodeficiency Virus infection in 300 South Indian patients. *Oral Dis* 2000; **6**: 152–157.
- 9 Ranganathan K, Umadevi M, Saraswathi TR *et al*. Oral lesions and conditions associated with Human Immunodeficiency Virus infection in 1000 South Indian patients. *Ann Acad Med Singapore* 2004; **33**: 375–425.
 - 10 Santos LC, Castro GF, de Souza IPR *et al*. Oral manifestations related to immunosuppression degree in HIV positive children. *Braz J Paed Dent* 2001; **12**: 135–138.
 - 11 Flaitz C, Wullbrandts B, Sexton J *et al*. Prevalence of orodental findings in HIV infected Romanian children. *Paediatr Dent* 2001; **23**: 44–50.
 - 12 Ramos-Gomez FJ, Hiltons JF, Canchola ALJ *et al*. Risk factors for HIV-related orofacial manifestations in children. *Paediatr Dent* 1996; **18**: 121–128.
 - 13 Pongsiriwet S, Iamaroon A, Kanjanavanit S. Oral lesions and dental caries status in perinatally HIV infected children in northern Thailand. *Int J Paed Dent* 2003; **13**: 180–185.
 - 14 Ramos-Gomez FJ, Flaitz C, Catapano P *et al*. Classification, diagnostic criteria and treatment recommendations for orofacial manifestations in HIV infected paediatric patients. *Pediatr Dent* 1999; **23**: 85–95.
 - 15 Williams DW, Lewis MAO. Isolation and identification of candida from the oral cavity. *Oral Dis* 2000; **6**: 3–11.
 - 16 Glick M. Orofacial disorders in children with HIV disease. *DCNA* 2005; **4**: 259–271.
 - 17 Ramos-Gomez FJ. Dental considerations for the paediatric AIDS/HIV patients. *Oral Dis* 2002; **8**: 49–54.
 - 18 Radhika C, Sai Subhasree R, Deborah AS. Paediatric HIV infection and its oral manifestation: a review. *Paediatr Dent* 1996; **18**(2): 106–113.
 - 19 Costa LR, Villena RS, Sucasas PS *et al*. Oral finding in paediatric AIDS: a case control study in Brazilian children. *ASDC J Dent Child* 1998; **65**: 186–190.
 - 20 Hamza OJM, Matee MIN, Simon ENM *et al*. Oral manifestations of HIV infection in children and adults receiving highly active anti-retroviral therapy [HAART] in Dar es Salaam, Tanzania. *BMC Oral Health* 2006; **6**: 12.
 - 21 Flanagan MA, Barasch A, Koenigsberg SR *et al*. Prevalence of oral soft tissue lesions in HIV infected minority children treated with highly active antiretroviral therapies. *Paediatr Dent* 2000; **22**: 287–291.
 - 22 Gelbier M, Lucas VS, Zervou NE *et al*. A preliminary investigation of dental disease in children with HIV infection. *Int J Paed Dent* 2000; **10**: 13–18.
 - 23 Howell RB, Jadiniski JJ, Palumbo P *et al*. Oral soft tissue manifestations and CD4 lymphocyte counts in HIV-infected children. *Paediatr Dent* 1996; **18**: 117–120.
 - 24 Kozinetz CA, Carter B, Simon C *et al*. Oral manifestations of paediatric vertical HIV infections. *AIDS Patient Care STDs*. 2000; **14**: 89–94.
 - 25 Sapp PJ, Eversole LR, Wysocki GP. *Contemporary Oral and Maxillofacial Pathology*, 2nd edn. St. Louis, Missouri: Mosby Publications, 2004: 395.
 - 26 Umadevi KMR, Ranganathan K, Pavithra S *et al*. Oral lesions among persons with HIV disease with and without highly active antiretroviral therapy in southern India. *J Oral Pathol Med* 2007; **36**: 136–141.
 - 27 Del Toro A, Berkowitz R, Meyerowitz C *et al*. Oral findings in asymptomatic and symptomatic HIV infected children. *Paediatr Dent* 1996; **2**: 114–116.
 - 28 Gill PS, Arora DR, Arora B *et al*. Lymphadenopathy an important tool guiding tool for detecting hidden HIV-positive cases: a six year study. *Int Assoc Physicians AIDS Care* 2007; **6**: 269–272.
 - 29 de Martino M, Tovo PA, Galli L *et al*. Features of children perinatally infected with HIV-1 surviving longer than 5 years. *Lancet* 1994; **343**: 191–195.
 - 30 Lucas SB, Peacock CS, Hounnou A *et al*. Disease in children infected with HIV in Abidjan. *BMJ* 1996; **312**: 335–338.
 - 31 Kumarasamy N, Solomon S, Flanigan TP *et al*. Natural history of human immunodeficiency virus disease in Southern India. *Clin Inf Dis* 2005; **36**: 79–85.
 - 32 Palme ID. Risk factors for Human Immunodeficiency Virus infection in Ethiopian children with tuberculosis. *Paediatr Infect Dis J* 2001; **20**: 1066–1072.
 - 33 Chan SB. Clinical manifestation and outcome of tuberculosis in children with acquired immunodeficiency syndrome. *Paediatr Infect Dis J* 1996; **15**: 443–447.
 - 34 Overturf GD. Technical report: Prevention of pneumococcal infections, including the use of pneumococcal conjugate and polysaccharide vaccines and antibiotic prophylaxis. *Paediatr* 2000; **106**: 367–376.
 - 35 Grayson W. The HIV-positive skin biopsy. *J Clin Pathol* 2008; **61**: 802–817.
 - 36 Bavdekar SB, Agarwal R. Clinically directed selective screening for HIV infection in hospitalized children. *Indian Paediatr* 2005; **42**: 1191–1197.
 - 37 Phanuphak N. Skin lesions: mirror image of oral lesion infections. *Adv Dent Res* 2006; **19**: 69–72.
 - 38 Nittayananta W, Chonowanna N, Winn T *et al*. Co-existence between oral lesions and opportunistic systemic diseases among disease among HIV-infected subjects in Thailand. *J Oral Pathol Med* 2002; **31**: 163–168.